



Available online at  
**ScienceDirect**  
[www.sciencedirect.com](http://www.sciencedirect.com)

Elsevier Masson France  
**EM|consulte**  
[www.em-consulte.com/en](http://www.em-consulte.com/en)



Review article

## Total fractures of the tibial pilon

F. Dujardin\*, H. Abdulmutalib, A.C. Tobenas

Service d'orthopédie-traumatologie, CHU de Rouen, 76031 Rouen, France



### ARTICLE INFO

#### Article history:

Accepted 20 June 2013

#### Keywords:

Tibial pilon  
 Synthesis  
 External fixation  
 Complications

### ABSTRACT

Complete fractures of the tibial pilon are rare and their treatment difficult. The pathophysiology includes three groups: (A) high-energy trauma (motor vehicle injuries), with severe articular and soft tissue lesions, (B) rotation trauma, (skiing accidents), with modest articular and soft tissue damage, and (C) low-energy trauma in elderly people. These three groups occasion very different problems and complications. In emergency situations, these fractures should be stabilized, most often using external fixation to restore length and prepare definitive fixation. The second stage can be applied once soft tissue healing is achieved. Two methods are discussed: internal plating and definitive external fixation. The first goal of treatment is to restore the articular surface, although this does not always prevent secondary arthritis. The second is to restore correct positioning of the foot as regard to the leg. The complication rate is high. Neither of the two fixation techniques has proven to be more effective. In group B, the two methods are similar, but external fixation seems to be safer in group A.

© 2014 Elsevier Masson SAS. All rights reserved.

### 1. Introduction

Destot was the first in 1911 to use the term “pilon”, stemming from the French term “pilon” and “plafond” continue to be used in the international literature. In 1987, Heim [1] presented the bases of rational management to the SOFCOT, recommending open internal osteosynthesis. Since then, several points have evolved: problems reproducing the good results reported by Heim; the development of external fixation, notably hybrid fixation, and the emergence of minimally invasive percutaneous osteosynthesis (MIPO). At the same time, fracture mechanisms have changed with very-high-energy injuries (motorcycle accidents rather than skiing accidents, falls from a height) as well as low-energy fractures in osteopenic subjects.

### 2. Definition

Total fractures of the tibial pilon are distal joint fractures of the tibia, with complete rupture of epiphyseal-diaphyseal continuity. They differ from fractures of the distal quarter, whether they be extra-articular or with a simple articular extension with little displacement, as well as from malleolar and marginal fractures that leave partial continuity with the diaphysis (fractures of the tibia are referred to as partial or marginal when they affect at least one-third of the pilon joint surface).

### 3. Anatomopathology

The lesional mechanism associates axial compression with variable angulation depending on the direction of the injury and the position of the foot. Bone architecture [2] (dense metaphysis and thin cortices) explains how the epiphysis “bursts” when a diaphyseal “wedge” penetrates it upon impact of the talus on the pilon.

The circumstances of the injury determine three groups that involve entirely different problems. Group A includes patients who have undergone very-high-energy injuries, with associated lesions as well as serious joint comminution and impaction (sometimes including the talus), which compromise the results (Fig. 1). The cutaneous lesions result from severe displacement and contusions (from outside in) with a high risk of secondary necrosis. Group B injuries result from rotation injuries, leading to spiroid fracture associated with joint separation, with no cartilage impaction (Fig. 2). The fracture can be open, but from inside out with no contusion. These are skiing accidents, which perhaps explains the good results in series from mountainous regions (Fig. 2). On the rise, group C fractures occur in elderly subjects; osteopenia, despite a low-energy injury, suffices to cause a greenstick fracture with angulation, as in children, with joint separation and frequent metaphyseal comminution (Fig. 3). The difficulties, notably osteosynthesis, stem from the bone quality and cutaneous trophicity.

In the typical forms, the elementary separations (Fig. 4) detach three fragments: anterolateral pedicle bone on the anterior tibiofibular ligament (Chaput fracture), posterior, on the posterior tibiofibular ligament (Volkman fragment), and medial, on the medial collateral ligament. These elementary fragments can

\* Corresponding author. Tel.: +33 02 32 88 01 64.

E-mail address: [Franck.dujardin@chu-rouen.fr](mailto:Franck.dujardin@chu-rouen.fr) (F. Dujardin).

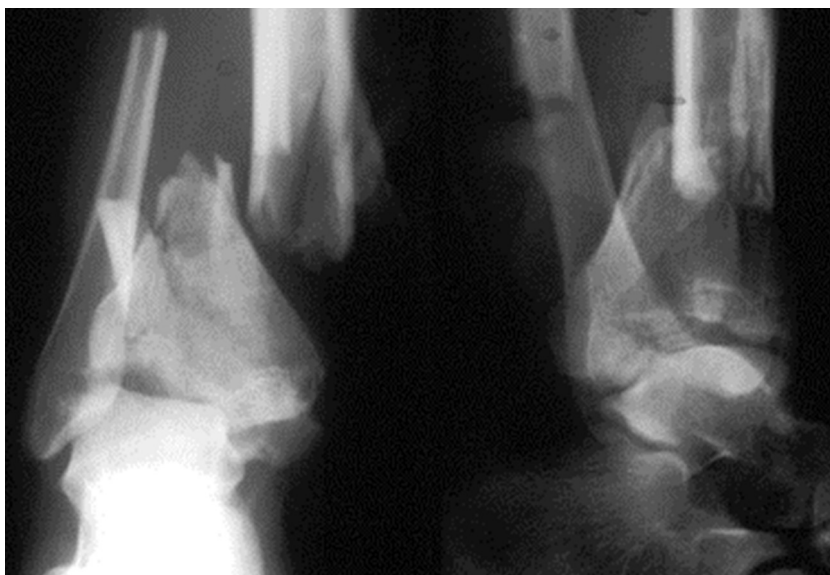

Fig. 1. Group A. Very-high-energy axial compression.

be more or less voluminous and sometimes split, and in the more severe forms, the distal extremity of the diaphysis is driven between them. This physiopathology requires three successive stages during reduction:

- pulling out the cortical wedge while restoring its length; in these cases, primary fibular reduction and stabilization can be useful;
- reduction-osteosynthesis of the epiphyseal fragments with reduction of the joint surface;
- restoration of diaphyseal-epiphyseal continuity.

There are no muscle insertions on the distal extremity of the tibia. Blood is supplied by the anterior and posterior tibial arteries, with a double proximal and distal network, interrupted by these total fractures. The medial subcutaneous side is supplied by branches coming solely from the anterior tibial artery, whereas

the lateral side also receives blood supply from the fibular artery branches.

The vascularization of the cutaneous edges has been examined in anatomical studies [3], which have led to advising a lateral rather than medial incision, which is more dangerous in this context.

#### 4. Classifications

Two international classifications have been elaborated in Switzerland, one by Ruedi and Allgower [4] (Fig. 5) and one by the AO [5] (Fig. 6). In the latter, these fractures belong to group 43, type C. These two classifications are very close. Interobserver reproducibility of the AO classification [6], based on X-rays, is “moderate” (Kappa, 0.41–0.60). Use of CT [7] improves this reproducibility.

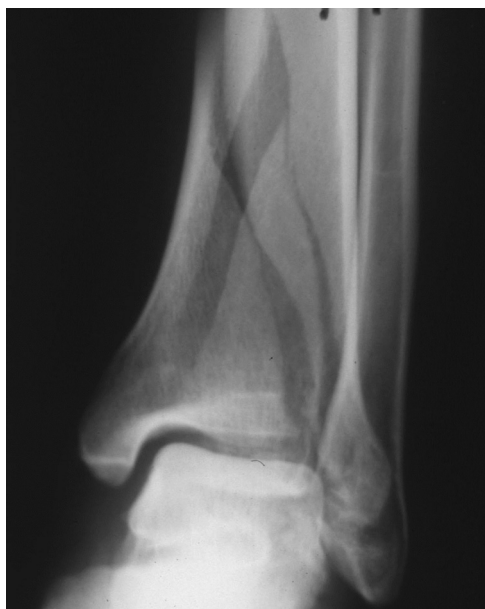

Fig. 2. Group B. Torsion component.

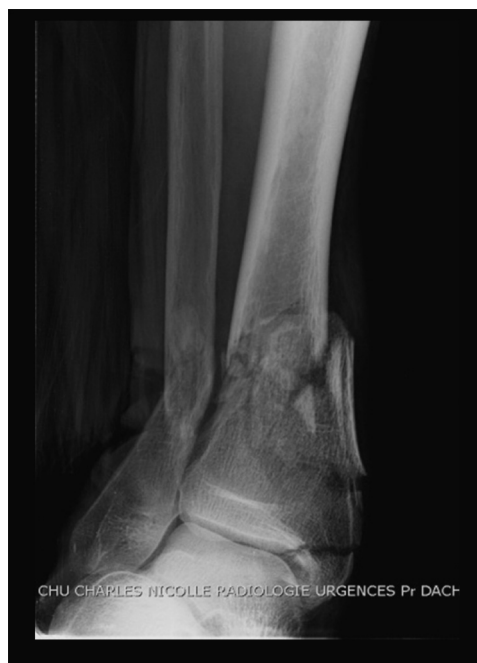

Fig. 3. Group C. Impaction, mainly metaphyseal, on an osteopenic bone.

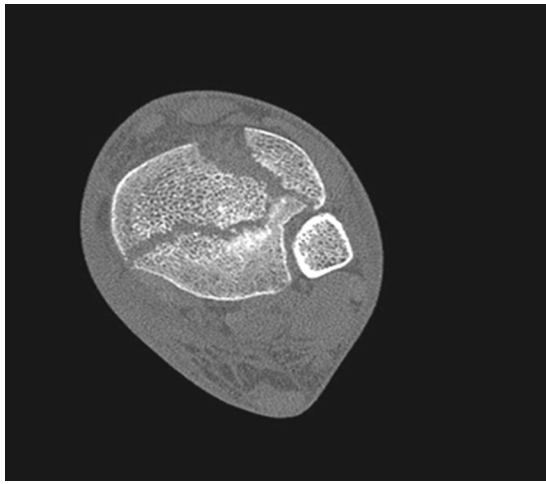
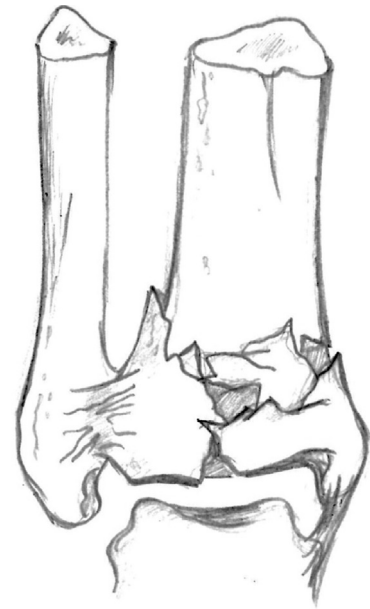

Fig. 4. CT showing the three elementary fragments.



## Type 43 C 2

Fig. 6. AO type 43-C2: simple articular fracture, but metaphyseal comminution. C1 and C2 fractures are similar to Ruedi and Allgower types I and III, respectively.

Topliss et al. [3] proposed a classification according to the orientation of the epiphyseal separation line, with one group having a coronal fracture line and one a sagittal fracture line, grouping approximately ten types. This classification, which individualizes the above-mentioned elementary fragments, is not used, like several others.

### 5. Epidemiology

We emphasize the epidemiology of group A fractures, the most severe, which readily occur in middle-aged males. One-third to one-half of these are open fractures. Their economic incidence is severe: 30–40% of the injured working before the accident go back to work at 2 years (14% for manual workers) and 35% remain with significant sequelae [8–10]. One patient out of two has multiple injuries, which influences treatment, convalescence, and rehabilitation.

### 6. Pretherapy assessment

Other than the initial standard X-rays, the definitive strategy, whatever method is chosen, requires CT exploration to specify the

fracture lines, detail the tibiofibular lesions, and the comminution and depression areas, which should be taken into account for the definitive treatment [11,12]. This CT should be done on an approximately reduced fracture, after the fracture has been aligned and stabilized in the emergency setting.

Assessment of the condition of the skin (contusion) and surrounding soft tissues is vital because it conditions the therapeutic strategy.

### 7. Surgical strategies and techniques

Nonsurgical treatment is exceptionally indicated in adults, reserved for the rare nondisplaced fractures or for nonwalking patients.

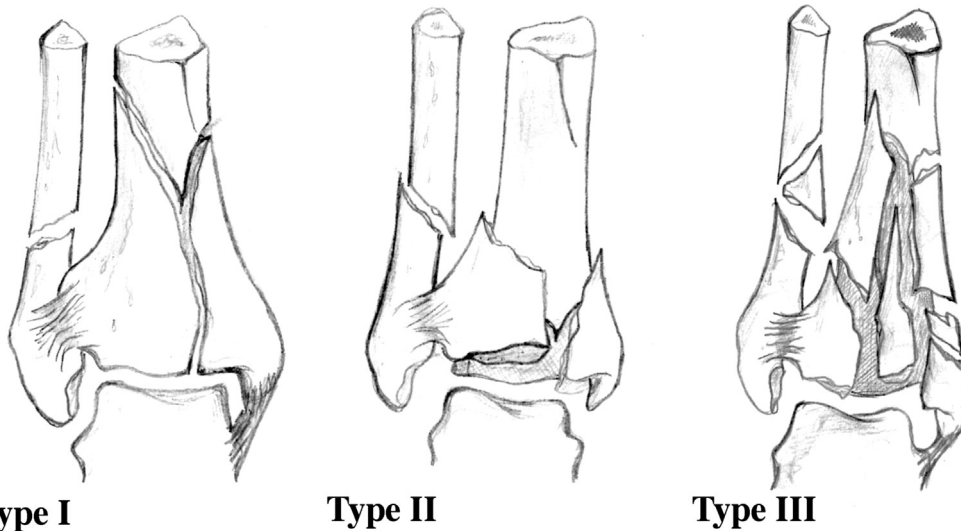


Fig. 5. Ruedi and Allgower classification, type I: simple metaphyseal and joint fracture lines, with little displacement; type II: significant displacement but only slight comminution; type III: comminution fracture with joint displacement.

## 7.1. History

The good results of open reduction internal fixation (ORIF) presented by the Swiss school in the 1980s contributed to their dissemination. However, in different contexts (group A patients rather than group B) these results were not reproduced, with very frequent complications, challenging the ORIF principle.

Several schools (notably Montpellier and Rouen) had long advocated the use of external fixators to prevent cutaneous complications, frequent in their experience. External fixation was tibio-calcaneal, bridging the ankle, with the joint reduction entrusted to “ligamentotaxis”. This method presented two disadvantages:

- joint reduction that was often insufficient, notably in cases of central impaction, which required adding percutaneous internal minimally invasive osteosynthesis to the external fixation [13];
- secondary stiffening of the ankle. Attempts at articulated external fixation aiming to counter this stiffening were disappointing and the method appears to have been abandoned.

In the 1990s, the principle of deferring the final osteosynthesis to a later time, after improvement of the cutaneous condition, came to the forefront. External fixation had also evolved, with partial use of the Ilizarov circular fixation concept: hybrid external fixation obviating the need for bridging the ankle and allowing minimal epiphyseal osteosynthesis.

Over the last few years, minimally invasive percutaneous osteosynthesis (MIPO) techniques have tended to replace ORIF and the epidemiology has changed, with a decrease in group A injuries and the emergence of group C injuries, which pose very different problems.

## 7.2. Internal plate osteosynthesis

### 7.2.1. *Principles methods: external fixation in the emergency setting followed by ORIF*

In an emergency setting, the fracture is reduced and stabilized with temporary external fixation (two diaphyseal pins and one or two calcaneal pins), a veritable “portable traction” [14]. This external fixation is generally medial.

Fibular osteosynthesis via the lateral approach is recommended because it is beneficial for reduction (restoring length and rotation), bone union [15], and the functional result. It should be stable, and therefore plate fixation should be preferred (or is recommended). If the patient’s general condition permits, it should be done at the same time as the external fixation.

The definitive tibial osteosynthesis takes place during the 2nd week, when the skin condition has improved and the CT assessment demonstrates the fracture lines as well as the comminution and impaction areas, making it possible to determine the reduction strategy. Performed under antibiotic treatment, this procedure uses an anteromedial approach distant from the lateral approach (Fig. 7). The first objective is to obtain anatomical reduction of the joint surface, including any central impaction, approached by prudently pushing away the medial fragment. Osteosynthesis of the epiphyseal fragments can be performed using screws or wires. The second objective is to restore the continuity between the epiphysis and the diaphysis on all sides of the metaphyseal lesions. This stabilization must be strong, capable of resisting varus stresses and should restore the AP and lateral axes of the distal extremity of the tibia, as well as the foot’s external rotation. The use of modern remolded plates facilitates this stage.

In comminution fractures, one must often complete exposure with a posterolateral approach to allow reduction and fixation of a marginal posterior fragment, the key to joint reduction [16] (Fig. 8).

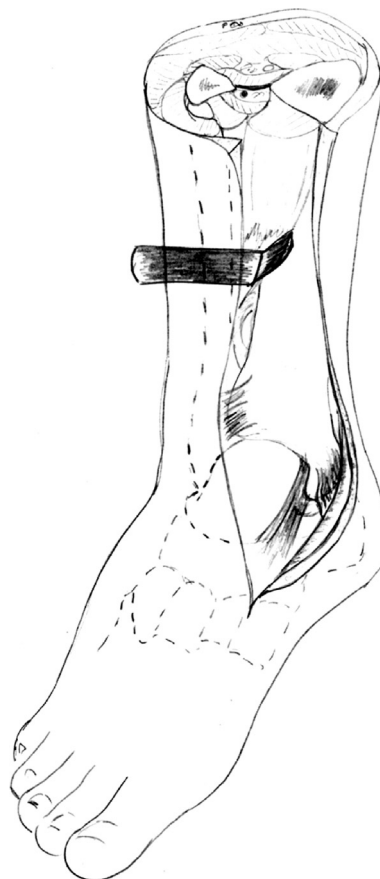

Fig. 7. Anteromedial approach (inside the anterior tibialis).

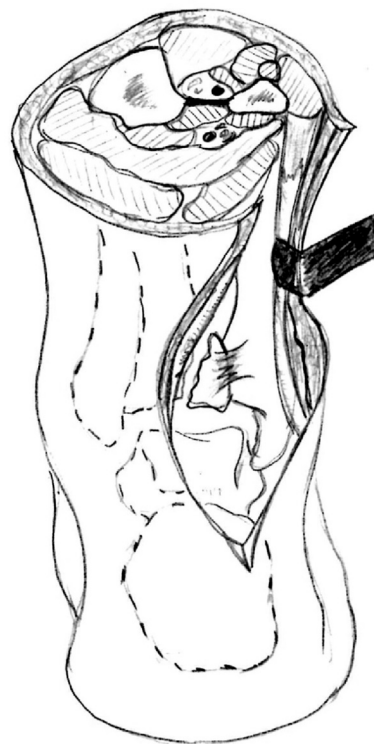


Fig. 8. Short posterolateral approach allowing reduction and direct fixation of a posterior marginal fragment.

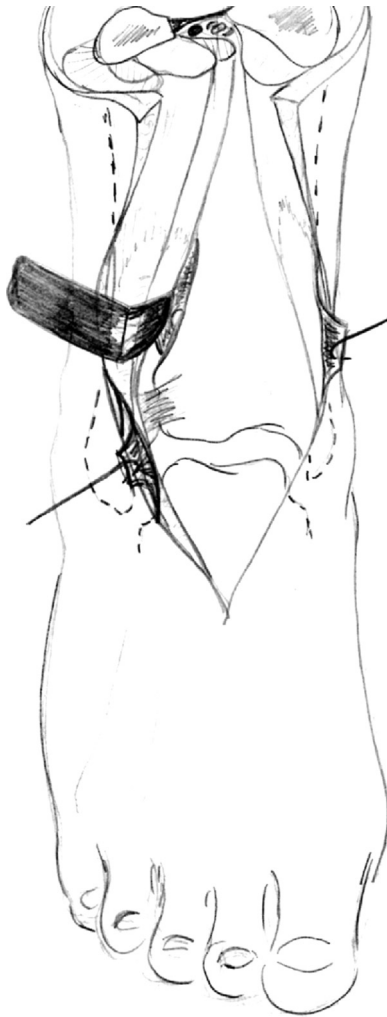


Fig. 9. Anterior approach (medial to the tibialis anterior tendon).

This third incision should be limited and distant from the two above-mentioned incisions and should be compatible with fibular osteosynthesis.

This anteromedial approach can be replaced with a pure anterior approach, medial to the tibialis anterior tendon (Fig. 9), which provides better exposure of the lesions.

Any filling of bone substance requires autografting. Use of bone substitutes or bone morphogenetic protein (BMP) has not been fully documented in this indication. It is essential to stabilize the reduction with a support screw.

Intraoperative verification of the joint reduction with the image intensifier is indispensable. The advantages of intraoperative endoscopic guidance are currently being evaluated [17].

Rehabilitation can be initiated early, with massages and drainage to combat edema, then recuperation of mobility. During this period, the fight against equinus is vital, notably using a posterior brace. The patient remains without load until bone union, approximately 3 months. Thromboembolic protection is required until true weightbearing is resumed. Regular radiological and clinical follow-up is indispensable during the first few weeks.

### 7.2.2. Locking plate fixation

Locking plate fixation in this indication does not seem to contribute a clear advantage and its indication remains imprecise [18]. It provides greater stability, which can be useful in cases of substantial comminution or osteopenia. One must be careful that their

greater thickness does not increase the risk of cutaneous complications [19]. In addition, this increased stability has been blamed for the occurrence of bone union delays [20].

### 7.2.3. Minimally invasive osteosynthesis

Some teams now recommend percutaneous osteosynthesis using a minimally invasive approach (MIPO [21]). Nonetheless, there are two contraindications:

- like all internal osteosynthesis, the existence of cutaneous lesions persisting during the second stage;
- substantial central subsidence for which a conventional approach is necessary.

### 7.2.4. Controversy: one or two stages?

Deferred internal osteosynthesis remains controversial today, even though it is defended by a majority of practitioners [11,18,21,22]. Other authors with large series report acceptable results of an early intervention in a single stage [23]. In a series of 95 patients, however, White et al. [23] reported six deep infections and ten imperfect reductions.

The MIPO technique could make it possible to reduce these complications and therefore allow an early intervention in a single procedure. In 32 fractures operated in the first 36 hours, Leonard et al. [24] reported only one malunion, with no deep infectious complications at 2 years in 83% of the cases. Nevertheless, a relevant analysis of these results would require precise knowledge of the distribution of the fractures treated in this way in the three physiopathological groups, which conditions the prognosis and the complication rates.

### 7.2.5. Internal osteosynthesis via other approaches

The anterolateral approach (Fig. 10) crossing a cutaneous covering supplied by two vascular sources [3] has been recommended by the Amiens school [25], joined by Mehta et al. [26].

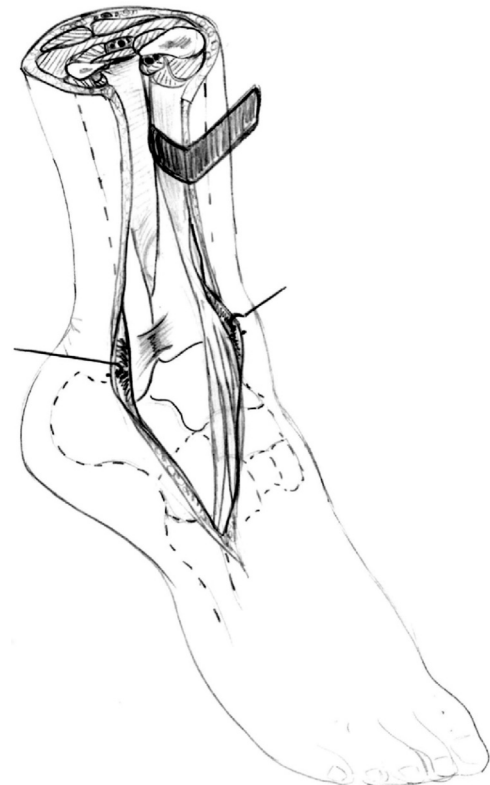
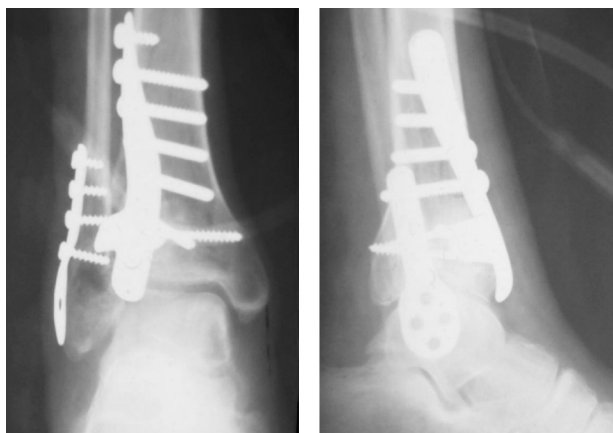


Fig. 10. Anterolateral approach.



**Fig. 11.** Anterolateral osteosynthesis.

Courtesy of Prof. Mertl.

Osteosynthesis calls for a specific plate (Fig. 11). The best environmental and vascular conditions for this approach mean it can be envisioned from the start, but others propose an eclectic attitude, using the anterolateral or anteromedial approach depending on the fragment lines and the fragments.

A complementary posteromedial approach may be necessary. This complementary approach should not be confused with the exclusive posteromedial approach, which is not recommended because of mediocre reductions and a high complication rate [27].

### 7.3. Definitive external fixation

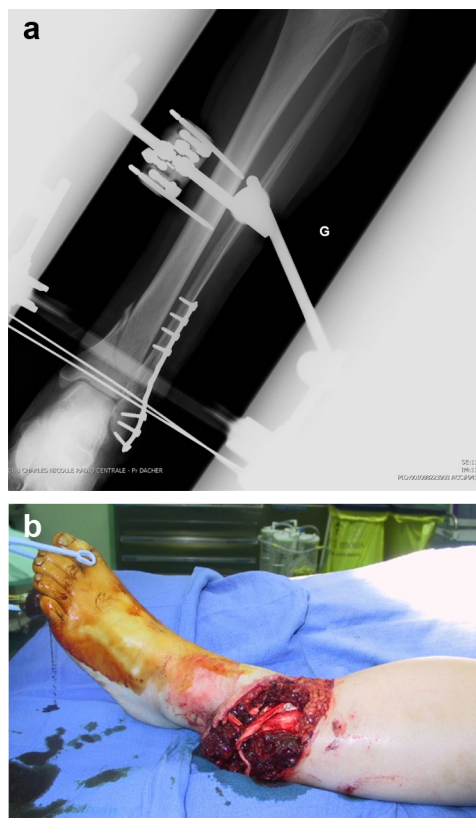
The principle is to dissociate joint reconstruction and restoration of epiphyseal-diaphyseal continuity, the work of the external fixation, thus avoiding an extensive opening from the metaphyseal-diaphyseal region. The three fundamental therapeutic principles remain unchanged:

- immediate alignment and stabilization of the fracture;
- precise restoration of the joint surface;
- fibula osteosynthesis, immediately or in the second phase.

#### 7.3.1. Hybrid external fixation

Use of hybrid external fixation is very widely recommended for two reasons. First, the ankle can be left free and is mobilized early. In addition, the circular epiphyseal assembly contributes great stability, including in patients with osteopenia [28]. These external fixators come with diaphyseal pins and 1.8-mm wires, tightened on a ring around the epiphysis. Theoretically, two are sufficient, three or four are preferable so as to have a “reserve” in case of septic complications and/or to set elementary fragments. These wires should be parallel to the joint space and follow trajectories that do not interfere with blood vessel or nerve pedicles.

The joint surface is generally precisely reconstructed in the second stage, after CT examination, based on which limited internal osteosynthesis is planned, with one or two screws, simple wires, or K-wires (Fig. 12). These epiphyseal wires “pin” the fragments and even stabilize them in compression using K-wires. These wires, or a sharp instrument, can be used like a joystick to percutaneously mobilize and reduce a displaced or impacted fragment. If this is impossible, a localized mini-epiphyseal approach is useful. Intraoperative endoscopic verification of the reduction is recommended by some to facilitate this stage [29,30].



**Fig. 12.** Hybrid external fixation, osteosynthesis of the tibial epiphysis K-wires allowing compression of the closed site.

#### 7.3.2. Tibiocalcaneal external fixation

In cases of very serious joint lesions, it may be necessary to permanently bridge the ankle with multiplanar tibiocalcaneal external fixation (tibiotalar for certain patients) so as to provide stability and sometimes obtain a reduction effect by ligamentotaxis. The prognosis is generally very poor and early arthrodesis can be the alternative.

#### 7.3.3. External fixation: one or two stages?

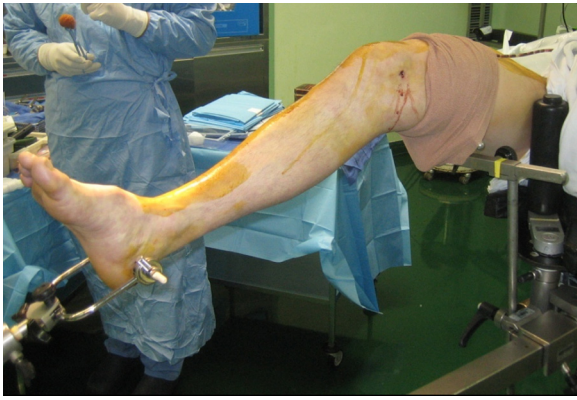Less than strategies with internal osteosynthesis, skin lesions require waiting, and in certain conditions, it is possible to perform all of the external fixation treatment in a single stage in the first few hours after trauma:

- the patient's general health must allow for a long surgical time without interfering with the treatment of vital lesions;
- the emergency radiological explorations must be sufficient to completely analyze the lesions, including impaction lesions;
- finally, a surgical team trained in the difficult management of these lesions must be available.

If these three conditions are met, the treatment can be carried out in its entirety upon the patient's arrival. Otherwise, it is preferable in the emergency situation to align and stabilize the fracture using a tibiocalcaneal multiplane assembly, which will be replaced by a hybrid assembly at a later time.

#### 7.3.4. Intraoperative distraction

Temporary intraoperative distraction is useful in fracture reduction and installation of final external fixation, with two possibilities: installation of the patient in traction on an orthopaedic table or use of a temporary tibiocalcaneal assembly.



**Fig. 13.** Intraoperative distraction on the orthopaedic table; cushion under the thigh and not the popliteal fossa.

On the orthopaedic table, the simplest option is to position the leg horizontally, with a counterpressure under the lower part of the thigh (and not in the popliteal fossa) (Fig. 13). Traction is ensured by a boot leaving the ankle free or by a transcalcaneal wire. Follow-up X-rays can be taken easily by turning the amplifier around the leg. The time “lost” during installation is largely gained during reduction and placement of the external fixation.

Using a tibiocalcaneal external fixation may seem simpler, but it does not provide as much freedom as the orthopaedic table.

#### 7.3.5. Complications with wires and pins

Superficial infection surrounding the wire is frequent, occurring in as many as 45% of patients [31], requiring surgical cleaning in 18%, but without deep infection.

These superficial infections should be prevented and treated earnestly so as to avoid osteitis and arthritis:

- it should be remembered that external fixation must be applied to an approximately reduced fracture to prevent cutaneous tension during secondary reduction;
- pin care consists in daily cleaning with a soft brush and a foamy solution;
- if inflammatory signs appear, care should be intensified and associated with antibiotic therapy started after taking local samples. If it does not evolve favorably, the wire should be removed and its trajectory cleaned surgically. This may lead to recommending placement of one or two additional wires in the epiphysis at the initial placement of external fixation.

#### 7.4. Nonreconstructible lesions

Lesions may be too severe for reconstruction. Early ankle arthrodesis is a good solution in these cases. It can also be performed secondarily after external fixation for emergency reduction.

When a very negative prognosis is established at the outset and understood by the patient, early arthrodesis reduces the resulting severity of the sequelae, the number of surgical procedures, and the very long period of disability [32].

Arthrodesis can be performed with screw, plate, or external fixation. Anterograde tibiotalar nailing associated with a lateral transmalleolar approach using pylon and fibula bone fragments for grafting has recently been proposed [33].

#### 7.5. Specific cases of open fractures

Open cutaneous lesions, particularly when severe, argue in favor of choosing a strategy based on safety with external fixation, healing, skin cover, and possibly secondary bone grafting [34].

However, in certain cases, a two-stage ORIF is possible if the skin lesions heal satisfactorily between the two stages, with no signs of inflammation [35]. This strategy, however, exposes the patient to a high risk of complications (which may require amputation), with mediocre functional results at 2 years, confirming the initial lesion severity, surpassing the cutaneous problem alone.

When the area is exposed, skin or artificial dermis grafts are not indicated on this deperiosteated bony foundation. For the same reason, directed healing, possibly using vacuum-assisted closure (VAC), is rarely possible and a flap, which can be fasciocutaneous (external supramalleolar, sural with a distal flap, or a crossleg flap) or muscular (soleus with a distal, pedis, or flexor hallucis flap), is required [36]. Occasionally a free flap must be used, the most often musculocutaneous with the latissimus dorsi. This flap is reliable and its large surface covers large tissue loss of the forefoot and the medial side of the ankle. It cannot be used in cases of septic complications.

In these cases of severe open lesions, early use of a vascularized flap can save the limb with significant functional gain [37].

## 8. Complications

### 8.1. Cutaneous necrosis

Cutaneous necrosis is frequent, particularly in group A injuries. Its onset should be treated energetically: hospitalization, repeated surgical cleaning, and antibiotic treatment adapted to the local samples. When tissue loss after excision is reduced, the wound can be closed; on the other hand, when it is more extensive, VAC treatment must be used, although chances of success are limited because of the mediocre local blood supply, or the wound should be covered.

### 8.2. Secondary displacement

Secondary displacement, most often varus, results from insufficient osteosynthesis. If this displacement occurs early, reduction and osteosynthesis should be redone if the skin condition permits. If the diagnosis is delayed, varus greater than 5° should not be neglected and the deformation should be reduced. Several techniques exist, depending on the severity of the angulation and the skin condition. Whether early or delayed, circular external fixation with progressive correction is valuable, notably when the initial deformations are complex and/or if the skin condition is worrisome.

### 8.3. Metaphyseal malunion

Onset of metaphyseal malunion is frequent. If the axes are preserved, the interfragment gap modest, and the site stable, external stimulation can be attempted [38]. In other cases, surgical treatment is necessary, with autologous corticocancellous grafting and sturdy osteosynthesis, with plate or external fixation. In the forms with substantial bone loss, intertibiofibular grafting (ITFG) is a method that remains reliable (good chance of bone union, low risk of infection).

### 8.4. Infectious complications, in particular osteitis

Infectious complications, in particular osteitis should immediately be treated aggressively, including surgical debridement-curettage (repeated if necessary) associated with significant bacteriological samples, i.e., deep and multiple. In such cases, internal tibial osteosynthesis should generally be replaced with external fixation.

**Table 1**  
Clinical results by method.

	Number of cases	Deep septic complications	Imperfect reductions	Malunion	Good results
Medial internal osteosynthesis in two phases [40–43]	139	2–10%	0–8%	2–5%	
Early medial internal osteosynthesis [23]	95	6.3%	10.5%		
Minimally invasive early medial internal osteosynthesis [24,44]	51	0	5%	3%	83%
Lateral internal osteosynthesis [45]	44	5%	7%	9.5%	
External fixation bridging the ankle with no epiphyseal osteosynthesis [43,46]	37	0	25%		
External fixation bridging the ankle with epiphyseal osteosynthesis [47,48]	39	8%	4–8%	4%	80%
Hybrid external fixation with minimally invasive epiphyseal osteosynthesis [30,31,43,49,50]	127	0–4%	0–8%	0–1%	70–85%

### 8.5. Tibiotalar arthritis

If the ankle is centered and the axes aligned, these cases of arthritis are sometimes remarkably well tolerated. Otherwise, surgical treatment must be envisioned. Sanders et al. [39] compared the results of arthroplasty and arthrodesis in this indication. Mobility following arthroplasty was disappointing, with a high complication rate requiring reintervention in one patient out of two. They concluded that arthrodesis was preferable. If arthritis occurs in a centered ankle, arthrodesis can be performed arthroscopically.

## 9. Results

Table 1 compares various recently published results. The series are heterogeneous and difficult to compare. Nevertheless, several data do stand out.

In absence of reduction and epiphyseal osteosynthesis, arthrodesis is required in one patient out of four.

As for internal osteosynthesis, MIPO reduces the rate of infectious complications, perhaps at the cost of an increase in joint reduction defects.

### 9.1. The historical comparative studies do not provide decisive proof

Bacon et al. [50] (ORIF, 28 cases, vs. circular external fixation, 14 cases) and Koulouvaris et al. [51] (external fixation bridging the ankle, 20 cases, vs. hybrid external fixation, 22 cases, vs. ORIF, 13 cases) demonstrated no clear differences other than a longer time to bone union when the ankle was bridged using an external fixator.

Endres et al. [31] (62 cases) demonstrated three advantages to hybrid external fixation compared to ORIF:

- no deep infection vs. 5%;
- no secondary arthrodesis vs. 8% (with 2 years of follow-up);
- 87% good functional results vs. 38%

On the other hand, in the external fixation group, 18% of the patients required care for infection on fixation wires (with no serious deep infection).

Kilian et al. (160 cases) concluded that there was less risk for septic infection in the association of external fixation plus minimally invasive osteosynthesis vs. two-stage ORIF [52].

Watson et al. [53] compared their treatments (107 patients) depending on cutaneous lesions: two-stage ORIF on moderate lesions (41 patients) vs. circular external fixation in cases of severe contusion or open fractures. Despite the poor initial prognosis in the external fixation group, the results were better in this group in terms of bone union, skin complications, and the results at 5 years of follow-up.

### 9.2. Comparative study

A single comparative study [54] including 35 cases treated with ORIF vs. 27 treated with external fixation bridging the ankle in addition to minimally invasive osteosynthesis, showed no difference between the two complication rates and the functional rates at 2 years of follow-up. However, one-quarter of the patients were lost to follow-up.

## 10. Conclusions

Analysis of the literature contributes little in terms of proof; nonetheless, several conclusions can be drawn.

Very widely accepted points:

- one must be highly vigilant with cutaneous lesions, which must be identified immediately, treated in adaptation to each case, and which contraindicate early surgery;
- temporary reduction and stabilization are required in the immediate stage after injury;
- it is indispensable to obtain foot alignment under the leg (axes and rotations), whereas exact reduction of the different metaphyseal fragments is not indispensable if this does not compromise stability or bone union;
- exact joint reduction is necessary, but it does not guarantee that the wound will not evolve to arthritis over the long-term;
- osteosynthesis of the fibula should be recommended;
- tibiofibular syndesmosis injuries should be stabilized with specific osteosynthesis of the anterolateral tubercle or using syndesmosis.

Personal reflections:

- definitive treatment cannot be unequivocal;
- the lesional pathophysiology is decisive:
  - A: very-high-energy injuries (motor vehicle accidents, fall from a height, etc.) with severe joint and cutaneous lesions, and frequent multiple injuries: definitive external fixation is safer because of the cutaneous risks. Complete treatment can perhaps be provided immediately in certain conditions. One must avoid blockage of the ankle. Minimally invasive epiphyseal osteosynthesis should be performed, immediately or secondarily, if necessary,
  - B: rotation injuries with spiroid fracture, few impaction lesions, less severe cutaneous lesions, and often a single injury: both dominant techniques, internal osteosynthesis, particularly with a minimally invasive approach, and hybrid external osteosynthesis plus minimally invasive epiphyseal osteosynthesis, provide comparable results;



- C: isolated impaction fractures in the elderly subject with osteopenia: hybrid external fixation provides good stability as does internal locking osteosynthesis.

The basic rule is to perform internal osteosynthesis in a second stage, toward the 2nd week, after the skin has healed. This rule can be ignored in certain highly favorable group B patients, notably with a minimally invasive or anterolateral approach.

Minimally invasive internal osteosynthesis (MIPO) has progressed compared to the open technique, provided that the joint lesions allow it.

It should be noted that the two broad currents, in historical terms, contrasting epiphyseal-diaphyseal plate osteosynthesis and external fixation, are currently merging, avoiding direct treatment of the metaphyseal area. One team has even just reported using locking plates extracutaneously, as in external fixation.

Questions that remain to be answered:

- what is the contribution of arthroscopy in joint observation and reduction?
- the anterolateral approach seems seductive, but large clinical series are required;
- what are the indications for immediate arthrodesis in very severe lesions?

#### Disclosure of interest

The authors declare that they have no conflicts of interest concerning this article.

#### References

- [1] Heim U. In: Duparc J, editor. Fractures du pilon tibial. Conférences d'enseignement. Paris: Expansion Scientifique Française; 1997. p. 35–51.
- [2] Topliss CJ, Jackson M, Atkins RM. Anatomy of pilon fractures of the distal tibia. *J Bone Joint Surg Br* 2005;87:692–7.
- [3] Aubry P, Fiévé G. Vascularisation osseuse et cutanée du quart inférieur de jambe. *Rev Chir Orthop* 1984;70:589–97.
- [4] Ruedi TP, Allgower M. The operative treatment of intra-articular fractures of the lower end of the tibia. *Clin Orthop Relat Res* 1979;138:105–10.
- [5] Muller ME, Allgower M, Schneider R, Willenegger H. Manual of internal fixation. Techniques recommended by the AO group. 3rd ed. Berlin: Springer Verlag; 1990.
- [6] Swiontkowski MF, Sands AK, Agel J, Diab M, Schwappach JR, Kreder HJ. Interobserver variation in the AO/OTA fracture classification system for pilon fractures. *J Orthop Trauma* 1997;11:467–70.
- [7] Ramappa M, Bajwa A, Singh A, Mackenney P, Hui A, Port A. Interobserver and intraobserver variations in tibial pilon fracture classification systems. *Foot* 2010;20:61–3.
- [8] Volgas D, DeVries JG, Stannard JP. Short-term financial outcomes of pilon fractures. *J Foot Ankle Surg* 2010;49:47–51.
- [9] Pollak AN, McCarthy ML, Bess RS, Agel J, Swiontkowski MF. Outcomes after treatment of high-energy tibial plafond fractures. *J Bone Joint Surg Am* 2003;85:1893–900.
- [10] Kline AJ, Gruen GS, Pape HC, Tarkin IS, Irrgang JJ, Wukich DK. Early complications following the operative treatment of pilon fractures with and without diabetes. *Foot Ankle Int* 2009;30:1042–7.
- [11] Scolaro J, Ahn J. Pilon fractures. *Clin Orthop Relat Res* 2011;469:621–3.
- [12] Tornetta 3rd P, Gorup J. Axial computed tomography of pilon fractures. *Clin Orthop Relat Res* 1996;323:273–6.
- [13] Biga N, Laurent M, Thomine JM. Le fixateur externe avec ostéosynthèse à minima du tibia. *Rev Chir Orthop* 1992;78:57–8.
- [14] Sirkin M, Sanders R, DiPascale T, Herscovici D. A staged protocol for soft tissue management in the treatment of complex pilon fractures. *J Orthop Trauma* 1999;13:78–84.
- [15] Lee YS, Chen SW, Chen SH, Chen WC, Lau MJ, Hsu TL. Stabilisation of the fractured fibula plays an important role in the treatment of pilon fractures. *Int Orthop* 2009;33:695–9.
- [16] Ketz J, Sanders R. Staged posterior tibial plating for the treatment of OTA 43-C2 and 43-C3 tibial pilon fractures. *J Orthop Trauma* 2012;26:341–7.
- [17] Poyanli O, Esenkaya I, Ozkut AT, Akcal MA, Akan K, Unay K. Minimally invasive reduction technique in split depression type tibial pilon fractures. *J Foot Ankle Surg* 2012;51:254–7.
- [18] Sirkin MS. Plating of tibial pilon fractures. *Am J Orthop* 2007;36:13–7.
- [19] Gupta RK, Rohila RK, Sangwan K, Singh V, Walia S. Locking plate fixation in the distal metaphyseal tibial fractures. *Int Orthop* 2010;34:1285–90.
- [20] Hasenboehler E, Rikli D, Babst R. Locking compression plate with minimally invasive plate osteosynthesis in diaphyseal and distal tibial fractures. *Injury* 2007;38:365–70.
- [21] Sommer C, Pesantez R. Tibia and fibula, distal. In: Babst R, Bavonratanevech S, Fernandez R, editors. Minimally invasive plate osteosynthesis. 2nd ed. AO publishing; 2012. p. 545–62 [ISBN (Americas): 9783131433923].
- [22] Blauth M, Bastian L, Krettek C, Knop C, Evans S. Surgical options for the treatment of severe tibial pilon fractures. *J Orthop Trauma* 2001;15:153–60.
- [23] White TO, Guy P, Cooke CJ, Kennedy SA, Droll KP, Blachut PA, et al. The results of early primary open reduction and internal fixation for treatment of OTA 43.C-type tibial pilon fractures. *J Orthop Trauma* 2010;24:757–63.
- [24] Leonard M, Magill P, Khayyat G. Minimally invasive treatment of high velocity intra-articular fractures of the distal tibia. *Int Orthop* 2009;33:1149–53.
- [25] De Lestang M, Hourlier H, Warlaumont C, Grodet H, Vives P. La voie d'abord antéro-externe pour le traitement des fractures de l'extrémité inférieure de jambe. *Rev Chir Orthop* 1985;71(Suppl. II):72–4.
- [26] Mehta S, Gardner MJ, Barei DP, Benirschke SK, Nork SE. Reduction strategies through the anterolateral exposure for fixation of type B and C pilon fractures. *J Orthop Trauma* 2011;25:116–22.
- [27] Bhattacharyya T, Crichlow R, Gobeze R, Kim E, Vrahas MS. Complications associated with the posterolateral approach for pilon fractures. *J Orthop Trauma* 2006;20:104–7.
- [28] Dujardin F, Ennedam J, Daragon A, Biga N, Thomine JM. Mesure expérimentale de la capacité de stabilisation des fractures métaphysaires supérieures de jambe par différents types de fixations externes. *Rev Chir Orthop* 1996;82:500–7.
- [29] Cetik O, Cift H, Ari M, Comert B. Arthroscopy-assisted combined external and internal fixation of a pilon fracture of the tibia. *Hong Kong Med J* 2007;13:403–5.
- [30] Kim HS, Jahng JS, Kim SS, Chun CH, Han HJ. Treatment of tibial pilon fractures using ring fixators and arthroscopy. *Clin Orthop Relat Res* 1997;334:244–50.
- [31] Endres T, Grass R, Biewener A, Barthel S, Zwipp H. Advantages of minimally invasive reposition, retention, and Ilizarov – hybrid fixation for pilon tibial fractures with particular emphasis on C2/C3 fractures. *Unfallchirurg* 2004;107:273–84.
- [32] Bozic V, Thordarson DB, Hertz J. Ankle fusion for definitive management of non-reconstructable pilon fractures. *Foot Ankle Int* 2008;29:914–8.
- [33] Niikura T, Miwa M, Sakai Y, Lee SY, Oe K, Iwakura T, et al. Ankle arthrodesis using antegrade intramedullary nail for salvage of non-reconstructable tibial pilon fractures. *Orthopedics* 2009;32:8.
- [34] Gardner MJ, Mehta S, Barei DP, Nork SE. Treatment protocol for open AO/OTA type C3 pilon fractures with segmental bone loss. *J Orthop Trauma* 2008;22:451–7.
- [35] Boraiah S, Kemp TJ, Erwtaman A, Lucas PA, Asprinio DE. Outcome following open reduction and internal fixation of open pilon fractures. *J Bone Joint Surg Am* 2010;92:346–52.
- [36] Masquelet AC. Atlas des lambeaux de l'appareil locomoteur. Montpellier: Sauramps médical; 2003.
- [37] Conroy J, Agarwal M, Giannoudis PV, Matthews SJ. Early internal fixation and soft tissue cover of severe open tibial pilon fractures. *Int Orthop* 2003;27:343–7.
- [38] Roussignol X, Currey C, Duparc F, Dujardin F. Indications et résultats avec le système à ultrasons Exogen dans la prise en charge des pseudarthroses. *Rev Chir Orthop* 2012;98:183–91.
- [39] Sanders R, Gorman RR, Ritter CA, Walling AK. Replacement versus arthrodesis for post-traumatic ankle arthritis. In: Annual Meeting of the OTA. 2004.
- [40] Patterson MJ, Cole JD. Two-staged delayed open reduction and internal fixation of severe pilon fractures. *J Orthop Trauma* 1999;13:85–91.
- [41] Sirkin M, Sanders R, DiPasquale T, Herscovici Jr D. A staged protocol for soft tissue management in the treatment of complex pilon fractures. *J Orthop Trauma* 2004;18:S32–8.
- [42] Kapukaya A, Subasi M, Arslan H. Management of comminuted closed tibial plafond fractures using circular external fixators. *Acta Orthop Belg* 2005;71:582–9.
- [43] Kapoor SK, Kataria H, Patra SR, Boruah T. Capsuloligamentotaxis and definitive fixation by an ankle-spanning Ilizarov fixator in high-energy pilon fractures. *J Bone Joint Surg Br* 2010;92:1100–6.
- [44] Kilian O, Bundner MS, Horas U, Heiss C, Schnettler R. Long-term results in the surgical treatment of pilon tibial fractures. *Chirurg* 2002;73:65–72.
- [45] Grose A, Gardner MJ, Hettrich C, Fishman F, Lorich DG, Asprinio DE, et al. Open reduction and internal fixation of tibial pilon fractures using a lateral approach. *J Orthop Trauma* 2007;21:530–7.
- [46] McCann PA, Jackson M, Mitchell ST, Atkins RM. Complications of definitive open reduction and internal fixation of pilon fractures of the distal tibia. *Int Orthop* 2011;35:413–8.
- [47] Tornetta P, Weiner L, Bergman M. Pilon fractures: treatment with combined internal and external fixation. *J Orthop Trauma* 1993;7:489–96.
- [48] Salton HL, Rush S, Schuberth J. Tibial plafond fractures: limited incision reduction with percutaneous fixation. *J Foot Ankle Surg* 2007;46:261–9.
- [49] Bacon S, Smith WR, Morgan SJ, Hasenboehler E, Phillips G, Williams A, et al. A retrospective analysis of comminuted intra-articular fractures of the tibial plafond: open reduction and internal fixation versus external Ilizarov fixation. *Injury* 2008;39:196–202.
- [50] Gaudinez RF, Malik AR, Szporn M. Hybrid external fixation in tibial plafond fractures. *Clin Orthop Relat Res* 1996;329:223–32.

- [51] Renzi B, Lavini F, Cavina P, Corain M, Bartolozzi P. The use of external fixation in fractures of the tibial pilon. *Chir Organi Mov* 2000;85:205–14.
- [52] Koulouvaris P, Stafylas K, Mitsionis G, Vekris M, Mavrodontidis A, Xenakis T. Long-term results of various therapy concepts in severe pilon fractures. *Arch Orthop Trauma Surg* 2007;127:313–20.
- [53] Watson JT, Moed BR, Karges DE, Cramer KE. Pilon fractures. Treatment protocol based on severity of soft tissue injury. *Clin Orthop Relat Res* 2000;375:78–90.
- [54] Davidovitch RI, Elkataran R, Romo S, Walsh M, Egol KA. Open reduction with internal fixation versus limited internal fixation and external fixation for high grade pilon fractures. *Foot Ankle Int* 2011;32:955–61.